ResearchGate

See discussions, stats, and author profiles for this publication at: https://www.researchgate.net/publication/290444702

Family with wind turbines in close proximity to home: follow-up of the case presented in 2007

Conference Paper · June 2010

CITATIONS
3

READS
1,328

7 authors, including:

Pedro Oliveira
Egaz Moniz School of Health and Science
60 PUBLICATIONS **608** CITATIONS

SEE PROFILE

José Martins dos Santos
Egaz Moniz School of Health and Science
50 PUBLICATIONS **582** CITATIONS

SEE PROFILE

Mariana Alves-Pereira
127 PUBLICATIONS **1,104** CITATIONS

SEE PROFILE

All content following this page was uploaded by Mariana Alves-Pereira on 15 January 2016.

The user has requested enhancement of the downloaded file.

14th International Meeting
on
Low Frequency Noise and Vibration and its Control
Aalborg, Denmark 9 – 11 June 2010

Family with wind turbines in close proximity to home: follow-up of the case presented in 2007

Nuno A. A. Castelo Branco Centro da Performance Humana, 2615 Alverca, Portugal
Email: vibroacoustic.disease@gmail.com

Teresa Costa e Curto
and
João Pedro da Costa Pereira Sociedade Hípica Portuguesa, Campo Grande, Lisboa, Portugal
Email: teresacurto@gmail.com

Luisa Mendes Jorge
and
Júlio Cavaco Faísca Universidade Técnica de Lisboa, Faculty of Veterinary Medicine, Lisbon, Portugal

Luis Amaral Dias Centro da Performance Humana, 2615 Alverca, Portugal
Email: vibroacoustic.disease@gmail.com

Pedro Oliveira
and
José Martins dos Santos Instituto Superior de Ciências da Saúde Egas Moniz, CiiEM, Almada Portugal
Email: pedrooliveira@hotmail.com

Mariana Alves-Pereira Universidade Lusófona-ERISA, Campo Grande, 376, 1749-024, Lisboa, Portugal
Email: m.alvespereira@gmail.com

Summary

In 2007, at the 2nd International Conference on Wind Turbine (WT) Noise, held in Lyon, France, low frequency noise (<500 Hz, LFN)-induced pathology, consistent with vibroacoustic disease (VAD), was shown to be emerging in the R. Family, exposed to residential LFN generated by 4 WT installed in close proximity (300-700 m) to their home. Herein, a follow-up is provided.

The wife and 2 children no longer reside within that home. Mr. R., however, must remain to care for the thoroughbred Lusitanian horses and bulls that he trains and breeds for bullfights. In addition to the continued deterioration of Mr. R's health and well-being, his financial situation is aggravated by the condition now appearing in his horses during the first year of life. Between 2000 and 2006, 13 healthy thoroughbred Lusitanian horses were born and raised on Mr. R's property. All horses (N=4) born or raised after 2007 developed asymmetric flexural limb deformities. WT began operations in November 2006. No other changes (constructions, industries, etc) were introduced into the area during this time.

Tissue analyses of the defected tendons were performed and revealed the classical features of LFN-induced biological responses: thickening of blood vessel walls due to proliferation of collagen in the absence of an inflammatory process.

1. Initial Disclaimer

The authors and the research team they represent would like to clarify that:
a) No member of this team is party to anti-technology sentiments;
b) Wind turbines, are considered welcome additions to modern technological society by all members of this team;
c) The data reported herein have been scrutinized under one, and only one, agenda - that of pure scientific inquiry;
d) In no way can or should this report be construed as a document arguing against the implementation of any and all wind turbines;
e) There are no commercial, financial or professional agreements (contractual or otherwise) between the accredited firms involved in noise measurements and any member of this team;
f) The consulting activities provided by these authors to Family R are of a purely academic and scientific nature and hence are pro bono.

2. Introduction

This report is a follow-up of a previous paper presented at the 2nd Wind Turbine Noise Conference, held in Lyon France in 2007. Herein, an update is given on the case of family R.

2.1 Background

In March of 2007, this team was contacted by an attorney-at-law representing the R. Family, in a case involving the placement of 4, 2 MW wind turbines (WT) near family R.'s property. Located between 321.8m and 642.0m from the residential building (Figs. 1, 2), the 4 WT became operational in November 2006. Two days later the R. family sought legal counsel to begin court proceedings in order to have the WT removed.



Figure 1. Aerial view of the WT home of Family R., isolated on upper left (dashed square) with the four wind turbines nearby (ovals).

Figure 2. WT home with the two of the turbines (arrows) at approximately 322m and 642m from the home.

Complaints of health effects reported in 2007:
"Mr. R has deep concerns about his memory loss, increased irritability and progressive intolerance toward audible noise, all of which he complained about at the very first meeting with this team, in March 2007. Both Mr. and Mrs. R have developed great difficulty in sleeping continuously throughout the night, as well as non-specific body pain. Upon visiting a general physician at the local State Health Center, Mr. R was prescribed 2 analgesics (anti-inflammatory and spasmolytic) and 2 tranquilizers (diazepam-based and short-term sleep-inducer) (...) In mid-March, Mr. and Mrs. R received a letter from their 12-year-old son's school, expressing concern for the growing difficulties of an otherwise outstanding student, 'particularly in English, Humanities and Physical Education. He progressed in Mathematics, which is a field that naturally attracts his type of intelligence. However, in the above mentioned coursework, it seems that the child has lost interest, makes a lesser effort, as if he were permanently tired. In Physical Education, an abnormal amount of tiredness is also observed. Is the child leading a healthy life? Does he sleep sufficient hours during the night?'" (Alves-Pereira & Castelo Branco 2007).

Noise assessments were subsequently conducted by an accredited firm hired by the R Family. Measurements were obtained in periods of 30-min, continuously for 12 days, between Apr 5th-16th, 2007. The lower limiting frequency was 1 Hz. Simultaneous and synchronized accelerometer and wind speed data were also acquired. Measurements were taken within the Master bedroom of Family R., in accordance with the procedures stipulated by Portuguese (NP 1730, Pt 1&2, 1996 and DL 9/2007, January 17th) and International Standards (ISO1996, 2003).

Figure 3 shows an example of the low frequency noise (LFN) measured within the R family home (Alves-Pereira & Castelo Branco 2007).

Wind Turbine Home With Same Wind Speed (5.4 Km/h)

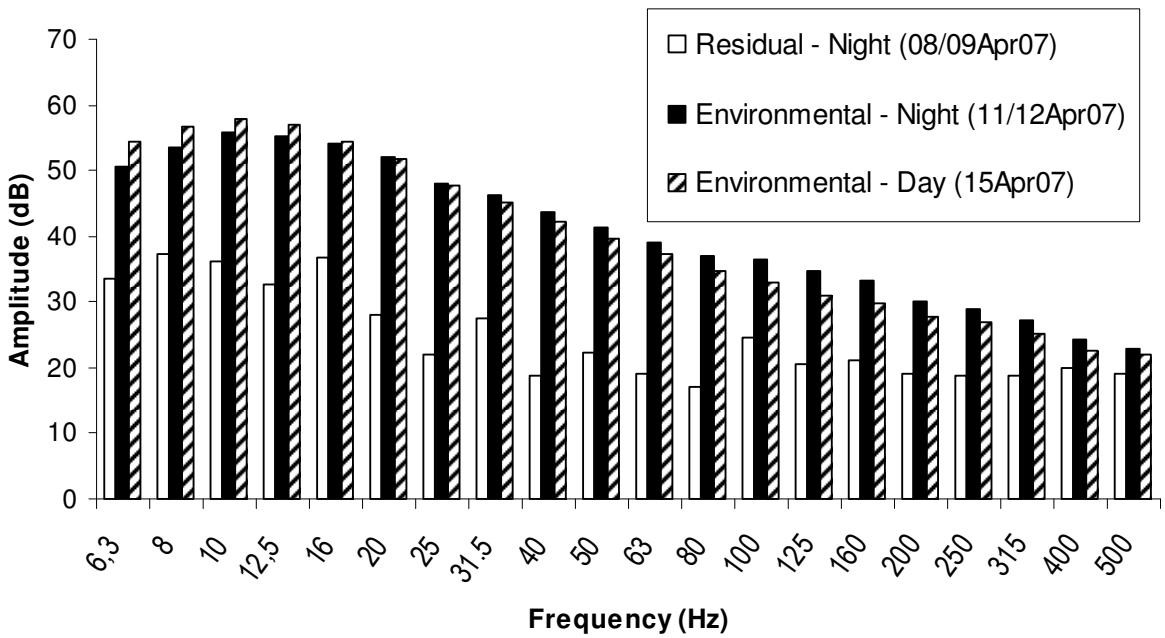

Figure 3. Comparison of 1/3 octave ILFN levels, in dBLinear, of the *Residual* (no WT blade movement) measurement and the *Environmental* (with rotating WT blades) measurement in the WT home Master Bedroom, with the same recorded wind speed.

The R. Family income is provided by breeding bulls and raising and training thoroughbred Lusitanian horses for bullfights. In 2007, Mr. R reported that his horses were exhibiting abnormal behaviours, such as lying down and sleeping during the day.

2.2 LFN-induced pathology

The biological effects of LFN exposure have been under study by this team for the past 3 decades. As a result, vibroacoustic disease (VAD) was defined as a LFN-induced extra-auditory pathology, characterized by the abnormal growth of collagen and elastin fibers in the absence of an inflammatory process (Castelo Branco 1999, Holt 2001, Castelo Branco & Alves-Pereira 2004, Alves-Pereira & Castelo Branco 2007b). Objective diagnostic tests to evaluate the severity of LFN-induced lesions have already been identified and were offered to the R family.

Echocardiograms of Mr. and Mrs. R. disclosed slight to moderate pericardial thickening (between 1.7 mm and 2.0 mm, normal for the equipment in use: <1.2mm). Respiratory drive was below normalized values in both adults (46%-53%, normal: >60%), suggesting the existence of brain lesions in the areas responsible for the neurological control of breathing.

Given the aforementioned school information, and since cognitive and memory disturbances are common and well documented in VAD patients (Castelo Branco 1999, Castelo Branco & Alves-Pereira 2004), the child received a neurophysiological evaluation.

Brainstem auditory evoked potentials disclosed asymmetries in the right and left nerve conduction times, and the right I-V interlatency value was at the threshold of normal values (4.44 ms). The endogenous evoked potential P300 recording occurred at 352 ms (normal: 300 ms). This measure reflects the time it takes to recognize and memorize infrequent stimuli. “Although this result is in accordance with the child’s

school report indicating that cognitive processes are affected, it is not possible to state that this situation is irreversible. Moreover, in children, P300 recordings often disclose variations that are difficult to interpret. Nevertheless, initial clinical signs of Stage-I VAD are characterized by this type of cognitive impairment and, as such, may be reversible at this clinical stage provided low frequency noise exposure is suspended" (Castelo Branco 2007).

3. Follow-up of Legal Proceedings

Legal proceedings are still ongoing. Nevertheless, given the gravity of the situation, the court has ordered that WT be shut down during evening and night hours (8 pm - 7 am), and that the WT closest to the home (322 m, Fig. 2) be permanently shut down. It was subsequently removed by its owners (See Figure 4A). Despite the court's decision, more WT continue to be installed in the immediate vicinity surrounding the R family home (See Figure 4B).



A B

Figure 4A and 4B. Aerial view of WT near Mr. R's farm in 2010. The long arrow (white) pointing upward indicates the site from where 1 of the 4 original WT was removed by its owners after a court order decreed that it be permanently shut down. (See Figure 1.) The circles indicate the remaining 3 WT of the original 4 and which, by court order, are forbidden to operate between 8 pm and 7 am. The smaller arrows (red) on the left pointing downward indicate WT installed after legal proceedings were initiated in 2007. The home is outlined by the dashed square.

4. Follow-up of Family Health

In September of 2007, after summer vacation during which the 12-year-old child was away from his home for 2 months, the neurophysiology results improved: endogenous evoked potential P300 recording occurred at 302 ms (normal: 300 ms). Mrs. R and the 2 children no longer reside within that home, having moved to a residential suburban area near Lisbon. Today, this child is again an outstanding student, at the top of his class.

Mr. R, however, must remain to care for the thoroughbred Lusitanian horses and bulls that he trains and breeds for bullfights. His health situation is continuously and visibly deteriorating. Intolerance to noise has become more severe. Situations compatible with an unregulated sympathetic nervous system have become frequent. Mr. R is currently undergoing a battery of neurophysiological tests which include multimodal evoked potentials, brain-mapping under different stimuli, and sleep studies. Mr. R's cognitive impairment has become more pronounced.

5. Equine Flexural Limb Deformities

Equine flexural limb deformities (EFLD) are clinical conditions that can occur in horse limbs causing the inability to place the hoof flatly on the ground. EFLD is often referred to as “tip-toeing”, because the hoof seems to be tilted off the ground, as if the horse were tip-toeing. Boxy foot or club foot are other common names for this condition.

EFLD can be caused by a variety of factors, such as congenital, nutritional, infectious and traumatic (Auer and Stick 2007). In adult horses, EFLD are mainly caused by infections or traumatic events. In foals, EFLD usually develop within 6 weeks to 8 months of age, and are most often a consequence of the inability of the deep digital flexor tendon to follow bone growth during the rapid growth period that occurs during the first year of life.

Treatment of EFLD does not have a bad prognosis when applied in a timely fashion. If at a sufficiently early age, splints complemented by medication may be used to help the foal straighten the limb, thus promoting the extension of the deep digital flexor tendon while accompanying bone growth. More severe situations may require a surgical procedure (desmotomy) to sever the accessory ligament of the deep digital flexor tendon (check ligament), thus releasing the flexor tendon and allowing it to take its position. In the most severe cases, the deep digital flexor tendon must also be severed. EFLD are highly undesirable situations, particularly for thoroughbreds, most often leading to permanent disability of the adult horse.

5.1. Horses born and raised on Mr. R’s farm

Between 2000 and 2006, 13 healthy thoroughbred Lusitanian horses were born and raised on Mr. R’s property.

All 4 horses born or raised after 2007 developed asymmetric EFLD. Figures 5 and 6 illustrate this condition.

Figure 5. *Espartaco* (Born 02May09, father: Zircão, mother: Vassoura.) Thoroughbred Lusitanian born and raised on Mr. R’s farm, exhibiting a normal right hoof and pronounced EFLD in the left limb.

Figure 6. *Engenheiro* (Born 17May09, father: Zircão, mother: Zizi.) Thoroughbred Lusitanian born and raised on Mr. R’s farm, exhibiting a normal left hoof and pronounced EFLD in the right limb.

All horses before and after 2007 had the same quantity and quality of diet, experienced the same housing conditions, and were submitted to the same daily exercise routines.

6. Tissue Analysis

Given the prior knowledge this team has acquired regarding expected outcomes of LFN exposure, and in an attempt to understand the remarkable frequency of EFLD in Mr. R's farm, biopsies were obtained from five different foals, as described in Table 1.

Table 1. Description of horses from which biopsies were obtained.

Case No.	Name & Birth Date	Origin	Procedure
1 Corrective Surgery	Canela 26FFEB07	Father: Operário Mother: Juvita *Born on Mr. R's farm*	EFLD corrective surgery with desmotomy of the check ligament in MAR08. After surgery, was allowed to spend time outdoors. Biposy obtained in MAR10.
2 Corrective Surgery	Desplante 02APR08	Father: Importante, Mother: Vassoura, *Acquired by Mr. R from Herdade das Silveiras in JUN09. At the same time, Vassoura was also acquired by Mr. R from the same breeders.*	Came to Mr. R's farm at age of 15 days. EFLD corrective surgery with desmotomy of the check ligament in JUN09. Biopsy obtained at the time of surgery in JUN09. After surgery, maintained in enclosed area.
3 (Control)	Dondoca 04ABR08	Father: Urânio Mother: Scalabitana. *Acquired by Mr. R from Olívio Pedrosa Marques in JUN09.*	Came to Mr. R's farm at the age of 14 months. Served as a control sample. Biopsy of left limb check ligament in JUN09.
4 Biopsy only	Espartaco 02May09 (See Fig. 5)	Father: Zircão, Mother: Vassoura. *Born on Mr. R's farm*	Biopsy of check ligament obtained in MAR10. Due to ongoing legal proceedings, no corrective surgery was performed.
5 Biopsy only	Engenheiro 17May09 (See Fig. 4)	Father: Zircão, Mother: Zizi. *Born on Mr. R's farm*	Biopsy of check ligament obtained in MAR10. Due to ongoing legal proceedings, no corrective surgery was performed.

Case 1 was born on Mr. R's farm in February 2007, developed EFLD and received corrective surgery in March 2008. After surgery, she was allowed to exercise in the outdoors. Today, the untreated limb has also developed asymmetrical EFLD and the treated limb seems to be recuperating (Figure 7). Check ligament biopsy was obtained in March 2010.

Case 2 (and his mother) was purchased by Mr. R in April 2008 and arrived at Mr. R's farm at the age of 15 days. EFLD developed over several months (Figure 9) and, in June 2009, corrective surgery was performed (Figure 10). After surgery, and unlike Case 1, this horse was not allowed to remain outdoors and was kept in the enclosed area. Today, no signs of EFLD are visible in either limb (Figure 8).

Figure 7. Case No. 1 (*Canela*) in March 2010. After surgery, she was allowed to go outdoors. EFLD is visible in both limbs.

Figure 8. Case No. 2 (*Desplante*) in March 2010. After surgery, he was maintained in enclosed area. No sign of EFLD is visible.

Figure 9. Case No. 2 (*Desplante*) before surgery. EFLD is visible in both forelimbs. Surgery was performed on left limb due to the larger severity in that limb.

Figure 10. Case No. 2 (*Desplante*). Desmotomy and biopsy of the check ligament of the left limb by author Costa Pereira (June 2009).

By June 2009, it had already been decided that biopsies would be taken for study. Within this scope, Mr. R purchased Case 3, from an entirely different breeder and age-matched with Case 2, in order to serve as control sample. In June 2009, check ligament biopsy was obtained from this horse.

Cases 4 and 5 (Figs. 5, 6) were born on Mr. R's farm and developed asymmetrical EFLD. Biopsies were obtained March 2010. No corrective surgery was performed on these two equines. Based on studies conducted by Auer and Stick (2006), no foal surgically treated for EFLD after 8 months of age had a favorable outcome.

Tissue fragments were prepared for light microscopy using standard gomori e trichromic masson stainings.

Check ligament fragments had normal appearances in all samples. In the three foals born and raised on Mr. R's farm (Cases 1, 4, 5), blood vessel walls were abnormally thickened due to the presence of collagen. Case 2 also disclosed collagen-thickened blood vessel walls. No such images were visible in fragments from Case 3. Cells normally associated with inflammatory processes were absent from all images.

7. Discussion

There are certainly a variety of pathways that can lead to incorrect positioning of the deep distal flexor tendon in equine forelimbs. Of the 13 foals born on Mr R's property before 2007, none developed EFLD. Since 2007, the 3 foals born and raised on this farm, all have developed EFLD. The foal purchased by Mr. R from Herdade das Silveiras, a prestigious breeder of Lusitanian thoroughbreds, arrived at Mr. R's farm at the age of 15 days and began showing signs of EFLD after several months (Case 2). This suggests that the agents responsible for EFLD were not present on Mr. R's farm until 2007, after which they seem to have started to influence the onset of EFLD. Three new foals more were born in 2010 but are, as yet, too young to manifest any visible signs of EFLD. Three mares are currently pregnant.

After surgery, Case 1 was allowed to remain in the outdoor pastures, while Case 2 was not. Mr. R's farm possesses a closed riding arena, adjacent to the stable area. Case 2 was exercised exclusively in this enclosed area. Case 1 has subsequently developed EFLD in the untreated limb while Case 2 has not. It would seem that the remaining within enclosed spaces might influence the onset of EFLD.

The asymmetrical development of EFLD in the forelimbs is commonly observed in most forms of EFLD, and is most probably related to the slightly asymmetrical load the equine places on one limb relative to the other when experiencing some degree of pain or discomfort. The asymmetry is associated with the degree of severity since, in most acquired EFLD, the onset is usually bilateral (Auer and Stick 2006). Other diseases affecting equine forelimbs can also develop first on one side and then on the opposite limb (navicular disease, for example).

Tissue analysis revealed:

- thickened blood vessel walls in the 3 foals born and raised on Mr. R's farm (Cases 1, 4, 5)
- thickened blood vessel walls in the foal who arrived on the farm at 15 days of age (Case 2)
- absence of thickened blood vessel walls in the equine age-matched with Case 2 and purchased from a different breeder.

These morphological changes in the absence of inflammatory processes are consistent with observations made over the past 30 years in autopsy, biopsy material from LFN-exposed individuals, and tissue fragments of LFN-exposed laboratory animals (Alves-Pereira & Castelo Branco 2007, for example). This particular type of tissue reorganization is the hallmark of LFN-induced response.

Since the year 2000 until today, the only significant change in the area of Mr. R's farm has been the installation of WT. No gas pipelines, large industrial plants, highways, railways, transportation terminals, or mining activities have been introduced in the vicinity within the last decade. The area is officially classified as rural. Under these circumstances, it is sensible to suspect that LFN is playing a role in the pathways leading to the onset of this form of EFLD.

8. Conclusions

This is a follow-up to the 2007 case of family R, exposed to LFN generated by WT, and who had begun to develop signs of LFN-induced pathology consistent with vibroacoustic disease. Although Mrs. R and both children no longer reside in this home and have been regaining their health, Mr. R must remain to care for thoroughbred Lusitanian horses and bull that he breeds for bullfighting. As a result,

his health has deteriorated rapidly, and now includes a more pronounced cognitive impairment and noise intolerance.

The pattern of onset of equine flexural deformities before and after the installation of WT in the farm's vicinity, led to check ligament biopsies of 4 foals raised on Mr. R's farm, and of 1 foal purchased by Mr. R from another breeder. It was shown that all 3 foals raised on Mr. R's farm disclosed the classical signs of LFN-induced responses: thickening of blood vessel walls due to proliferation of collagen in the absence of inflammatory processes. The purchased yearling foal did not exhibit these morphological features.

The results presented herein strongly suggest that the presence of LFN-generating WT in the vicinity of this horse breeding farm can play a significant role in the triggering and onset of equine flexural limb deformities.

References

M Alves-Pereira, NAA Castelo Branco. "On the impact of infrasound and low frequency noise on public health - two cases of residential exposure", RLCTS, 4(2), 186-200, 2007a.
http://revistas.ulusofona.pt/index.php/revistasaude/article/viewFile/670/564

M Alves-Pereira, NAA Castelo Branco NAA. "Vibroacoustic disease: Biological effects of infrasound and low frequency noise explained by mechanotransduction cellular signalling", Progress Biophysics & Molecular Biology, 93:256-279, 2007b.

JA Auer, JA Stick (Eds): "Equine Surgery" (3rd Ed.). St. Louis: Saunders Elsevier, pp 1150-1165, 2006.

NAA Castelo Branco. "The clinical stages of vibroacoustic disease", Aviation, Space & Environmental Medicine, 70 (3, Suppl): A32-9, 1999.

NAA Castelo Branco, M Alves-Pereira. "Vibroacoustic disease", Noise & Health, 6(23): 3-20, 2004.

NAA Castelo Branco. "Medical report on Family R". Documentation pertaining to legal proceedings in this case, 2007.

BD Holt. "The pericardium". In: V Furster , R Wayne Alexander, F Alexander, editors. Hurst's The Heart. New York: McGraw-Hill Professional Publishing, pp2061-82, 2001.

View publication stats